Sarcoma uterino oculto em indicações benignas

Dr. Marcelo Simonsen
GINECOLOGIA LAPAROSCÓPICA
ONCOLOGIA GINECOLÓGICA

Problema

- Maioria dos casos diagnosticados retrospectivamente

Cheng et al. BMC Women's Health (2022) 22:495

Estudos populacionais

- 1/4971 (JMIG 2015)
- 1/2180 (Arch Gynecol Obstet 2015)
- 1/350 (womens Heath issues 2016)
- 1/335 (JMIG 2016)
- 1/752 HT simples (Am J Obstet Gynecol 2019)
- 1/256 Mioma (Am J Obstet Gynecol 2019)
- 1/147 (BMC Womens Health 2022)

Problemas do diagnóstico retrospectivo

- Fragmentação da peça
- Dificulta o exame anátomo patológico
- Piora prognóstico
- Equipe despreparada
- Paciente despreparada

Problemas da fragmentação: I Cirúrgicos

Dr. Marcelo Simonsen
GINECOLOGIA LAPAROSCÓPICA
ONCOLOGIA GINECOLÓGICA

- Geralmente úteros >350g mais trabalhosos
- Risco mecânico imediato pequeno
- Leiomatose peritoneal (65 meses após!) → menos de 1% dos casos (leiomiomatose peritoneal disseminada)
- Disseminação tumoral

Perkins et al Womens health issues 2016
Janire et al CJOG 2016

Problemas da fragmentação:
II Patológicos

Dr. Marcelo Simonsen
GINECOLOGIA LAPAROSCÓPICA
ONCOLOGIA GINECOLÓGICA

- Tamanho tumoral?
- Sarcomas de estroma endometrial precisam da interface tumor- miometrial para melhor diagnóstico (as vezes apenas 3 mm de invasão)
- Risco de recidiva até 20 anos

Sanneh et al Obstet Gynecol 2020

Impacto prognóstico de morcelar sarcoma

Dr. Marcelo Simonsen
GINECOLOGIA LAPAROSCÓPICA
ONCOLOGIA GINECOLÓGICA

Table 4 LASH and uterine sarcoma

Laparoscopic supracervical hysterectomy

Patient	Patients age (years)	Body mass index	Date of operation	Uterus weight (g)	Histology	Last gyn. examination	Follow-up (months)	Recurrence
1	49	27.4	04.12.2002 06.12.2002	567	Leiomyosarcoma No tumor in cervix, adnexa, lavage	05/2014	137	No
2	44	22.1	25.03.2008 14.07.2008	106	Endometrial stromal sarcoma (low grade) No tumor in cervix, adnexa, lavage	05/2010	26	No
3	43	29.0	17.06.2008 02.10.2008	590	Endometrial stromal sarcoma (low grade) No tumor in cervix, adnexa lavage	03/2014	57	No
4	48	21.2	13.05.2008 12.08.2008	90	Endometrial stromal sarcoma (low grade) No tumor in cervix, adnexa, lavage	05/2011	36	No
5	49	33.7	04.11.2008 07.10.2009	1000	Leiomyosarcoma Peritoneal carcinomatosis and bone metastases		13	Yes Death 12/2009
6	59	24.8	15.01.2009 26.02.2009	440	Endometrial stromal sarcoma No tumor in cervix, adnexa, lavage	12/2012	36	No

- 10.731 histerectomias MIC clinic
- Indicão 80% mioma sintomático
- Avaliou diferentes cânceres

→ sarcoma de estroma

→ leiomiossarcoma

Bojahr et al Arch Gynecol Obstet 2015

Impacto prognóstico de morcelar sarcoma

Dr. Marcelo Simonsen
GINECOLOGIA LAPAROSCÓPICA
ONCOLOGIA GINECOLÓGICA

Table 3 LASH and endometrial carcinoma

Patient	Patients age (years)	Body mass index	Date of operation	Uterus weight (g)	Histology	Last gyn. examination	Follow-up (months)	Recurrence
1	57	43.6	16.03.2000	300	Adenocarcinoma in polyp, pT 1a	04/2014	169	No
			27.03.2000		No tumor in cervix, adnexa, lavage			
2	60	29.7	25.01.2001	84	Endometrioid adenocarcinoma G1	07/2013	151	No
			12.02.2001		No tumor in cervix, adnexa, lavage, pT 1b			
3	50	21.6	26.09.2000	150	Endometrial cancer in situ, pT 1a	No information available		
4	45	19.7	13.05.2004	400	Undifferentiated endometrial cancer, pT 1a/b, N1 (5/17), MX, V0, L0; FIGO III C	06/2009	61	No
			03.06.2004		No tumor in cervix, adnexa, 5 positive lymph nodes			
5	46	27.9	29.07.2008	157	Endometrioid adenocarcinoma pT1a G2	11/2009	16	No
			15.08.2008		No tumor in cervix and 20 lymph nodes	Moved to another city, lost to follow-up		
6	46	50.0	03.12.2008	230	Endometrioid adenocarcinoma, pT1a G1–2	05/20013	53	No
			02.01.2009		No tumor in cervix, adnexa, lavage and 28 lymph nodes			
7	58	29.6	01.03.2001	50	Endometrioid adenocarcinoma, pT1b G1	05/2014	38	No
			12.04.2011		No tumor in cervix, adnexa, lavage			
8	49	20.7	06.12.2011	26	Endometrioid adenocarcinoma, pT1a G1	05/2014	30	No
			31.01.2012		No tumor in cervix, adnexa, lavage			

→ CA de endométrio

Bojahr et al Arch Gynecol Obstet 2015

Impacto prognóstico de morcelar sarcoma

Dr. Marcelo Simonsen
GINECOLOGIA LAPAROSCÓPICA
ONCOLOGIA GINECOLOGICA

Table 1

Details of patients subsequently diagnosed with sarcomas: TLH group

Case no.	Age (yr)	Complaints	Sonography	Type of surgery	Diagnosis (histopathology)	Type of morcellation	Specimen weight (g)	Follow-up
1	51	Heavy menstrual bleeding	Enlarged, multiple myomas 6–8 cm	TLH with bilateral salpingectomy (both ovaries conserved) (2005)	LMSsarcoma	Vaginal morcellation	1100	Laparotomy with BSO, chemotherapy Alive
2	53	Heavy menstrual bleeding	Uterus enlarged with myoma 6 × 7 cm (type 4)	Total laparoscopic hysterectomy with left salpingo-oophorectomy (2008)	LMSsarcoma	Vaginal morcellation	200	Chemotherapy and radiation Alive
3	49	Abdominal pain	Uterus enlarged with multiple myomas: posterior wall myoma 6.9 × 5.2 cm (type 6) and anterior wall myoma 3.6 × 2.9 cm	TLH with bilateral salpingectomy (2013)	Low-grade endometrial stromal cell sarcoma	Vaginal morcellation	300	Bilateral oophorectomy after 1 month Alive
4	46	Dysmenorrhea	Uterus enlarged with myoma of 8 × 7 cm (types 2–5)	TLH with bilateral salpingectomy (both ovaries conserved) (2014)	LMSsarcoma	Vaginal morcellation	700	Chemotherapy and radiation Alive
5	36	Heavy menstrual bleeding	Uterus, enlarged with anterior wall myoma 7.2 × 5.3 cm (types 2–5) and cervical myoma 6 × 3 cm	TLH with right salpingo-oophorectomy with left salpingectomy (left ovary conserved) (2014)	Stromal cell sarcoma	Vaginal morcellation	300	Did not receive any surgical treatment Alive

BSO = bilateral salpingo-ophorectomy; LMS = leiomyosarcoma; TLH = total laparoscopic hysterectomy.

Paul et al JMIG 2015

Impacto prognóstico de morcelar sarcoma

Dr. Marcelo Simonsen
GINECOLOGIA LAPAROSCÓPICA
ONCOLOGIA GINECOLOGICA

Table 2

Details of patients subsequently diagnosed with sarcomas: myomectomy group

Case no.	Age (yr)	Clinical feature	Sonography	Type of surgery	Diagnosis (histopathology)	Type of morcellation	Specimen Weight (g)	Follow-up
1	12	Heavy menstrual bleeding	Poorly circumscribed mass 2.5 cm in the endometrium	Hysteroscopic resection of submucous myoma (2004)	Low-grade endometrial stromal sarcoma	Resectoscope	60	Died 4 years after surgery
2	34	Secondary infertility, heavy menstrual bleeding	Uterus with one large myoma 7 cm	LM (2007)	LMS	Power morcellation	200	TAH with BSO (another center) followed by chemotherapy Died 2 years after surgery
3	37	Primary infertility	Uterus with myoma 10 × 9 cm and 2.7 × 2.1 cm (types 2–5)	Diagnostic hystero scopy with LM (2013)	LMS	Power morcellation	180	Received chemotherapy followed by TAH with BSO 7 months after LM Alive

BSO = bilateral salpingo-ophorectomy; LM = laparoscopic myomectomy; LMS = leiomyosarcoma; TAH = total abdominal hysterectomy.

Paul et al JMIG 2015

Impacto prognóstico de morcelar sarcoma

- n= 293 sarcomas
- Aumento das recidivas abdominais (40-> 70%)
- Pior sobrevida livre de doença

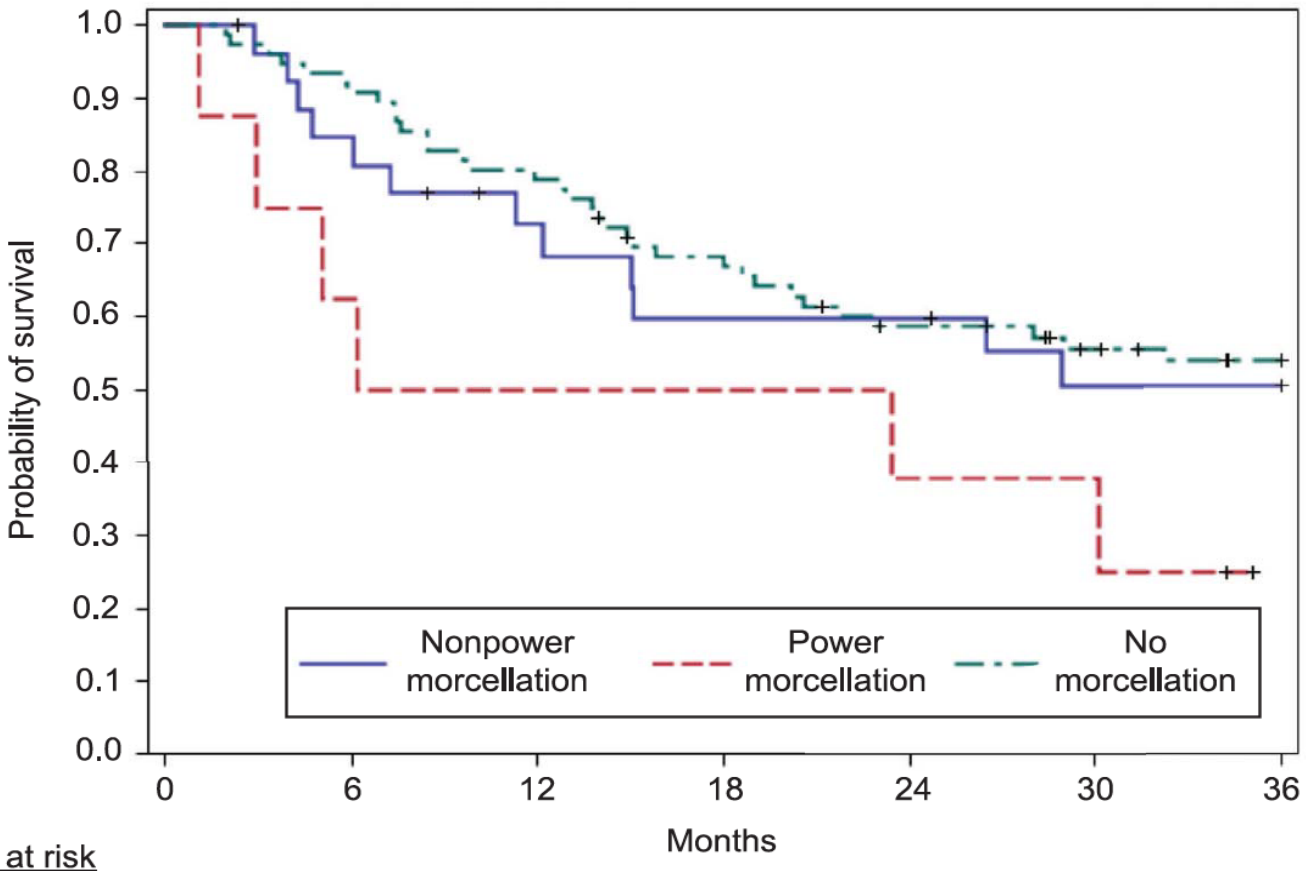

Number at risk							
No morcellation	76	69	60	50	41	35	30
Power morcellation	8	5	4	4	3	3	0
Nonpower morcellation	27	22	17	14	14	11	11

Raine-bennett Obstet & Gynecol 2016

Impacto prognóstico de morcelar sarcoma

- Pior sobrevida global no 1º ano

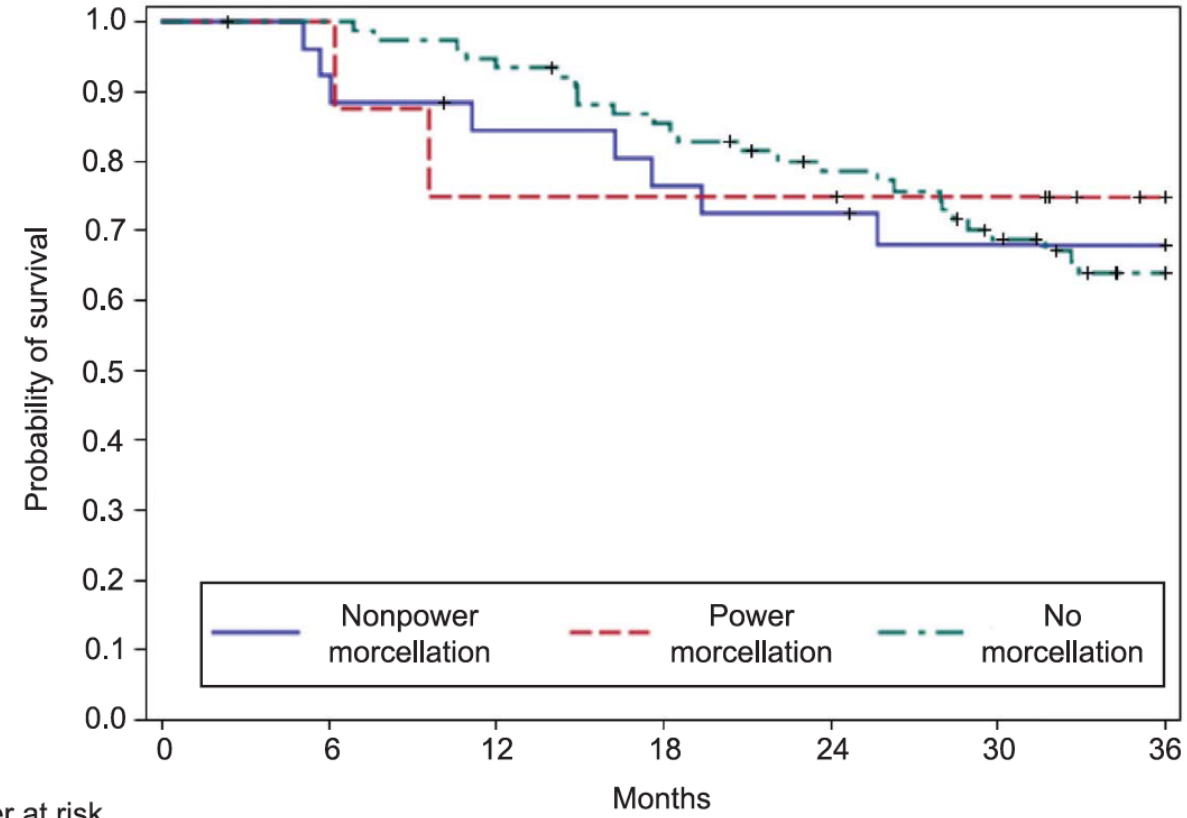

Number at risk							
No morcellation	76	76	72	64	56	47	38
Power morcellation	8	8	6	6	6	5	1
Nonpower morcellation	27	24	21	19	18	16	16

Raine-bennett Obstet & Gynecol 2016

Prognóstico de sarcomas

Estadio	Sobrevida 5 anos
localizada	60%
Pélvica	37%
Distante	12%
Global	38%

NCCN Guidelines Version 2.2023
Uterine Neoplasms

T	FIGO Stage	Primary Tumor
TX		Primary tumor cannot be assessed
T0		No evidence of primary tumor
T1	**I**	Tumor limited to the uterus
T1a	**IA**	Tumor limited to the endometrium/endocervix
T1b	**IB***	Tumor invades less than or equal to half myometrial invasion
T1c	**IC***	Tumor invades more than half myometrial invasion
T2	**II**	Tumor extends beyond the uterus, within the pelvis
T2a	**IIA**	Tumor involves adnexa
T2b	**IIB**	Tumor involves other pelvic tissues
T3	**III**	Tumor infiltrates abdominal tissues
T3a	**IIIA**	One site
T3b	**IIIB**	More than one site
T4	**IVA**	Tumor invades bladder or rectum

Prognóstico de outros tumores ginecológicos

Dr. Marcelo Simonsen
GINECOLOGIA LAPAROSCÓPICA
ONCOLOGIA GINECOLÓGICA

Sobrevida 5 anos

	E1	E2	E3	E4
Colo	88%	67%	35%	10%
Ovário	93%	68%	27%	13%
Útero	92%	74%	48%	15%

Cirurgia aberta?

Laparoscopic hysterectomy with morcellation versus abdominal hysterectomy for presumed fibroids in premenopausal women: a decision analysis

Clinical outcomes: per 100,000 women undergoing hysterectomy for presumed fibroids

Outcome	Laparoscopic hysterectomy: Base-case [range] *	Abdominal hysterectomy: Base-case [range] *	Incremental Difference (Laparoscopic–abdominal)
Leiomyosarcoma cases	120	120	n/a
Leiomyosarcoma deaths	86 [50-353]	71 [41-289]	15
Hysterectomy-related deaths	12 [10-12]	32 [28-32]	–20
Total deaths	98 [60-365]	103 [69-321]	–5
Transfusion	2,400 [1,300-3,500]	4,700 [4,300-4,700]	–2,300
Venous thromboembolism	690 [30-900]	840 [720-840]	–150
Vaginal cuff dehiscence	640 [200-890]	290 [150-600]	350
Abdominal wound infection	1,500 [55-1,500]	6,300 [6,300]	–4,800
Hernia	710 [140-900]	4,500 [4,500-9,800]	–8,090
Quality-adjusted life years	499,171 [499,062-499,280]	490,711 [482,733-486,270]	8,460

* Sensitivity analyses were conducted using the ranges outlined in Tables 1 and 3, i.e. the one-way sensitivity analysis for each input

Siedhoff et al; Am J Obstet Gynecol. 2015

Cirurgia aberta?

Laparoscopic hysterectomy with morcellation versus abdominal hysterectomy for presumed fibroids in premenopausal women: a decision analysis

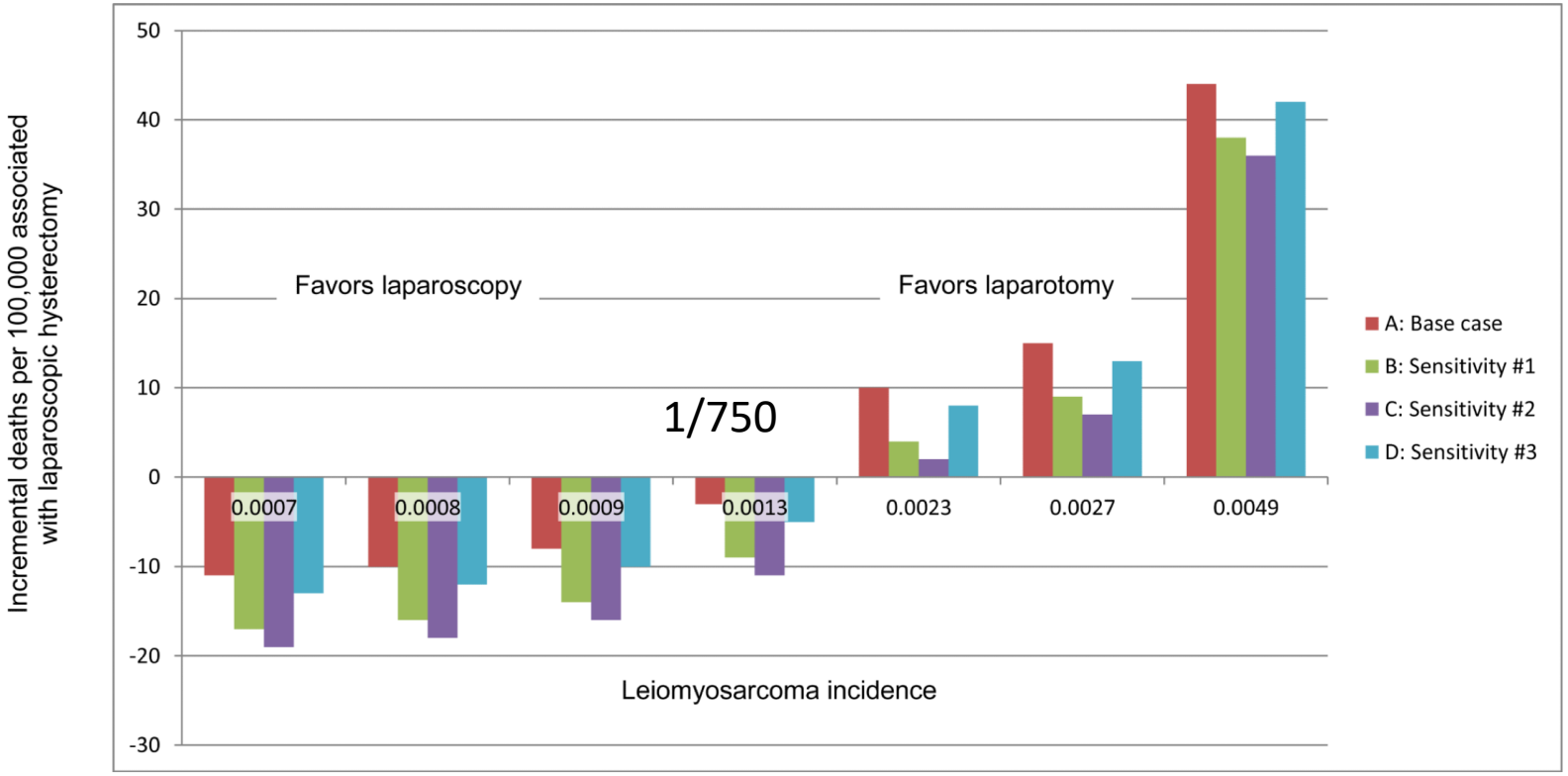

Cirurgia aberta é mais mórbida que vlp!

Siedhoff et al; Am J Obstet Gynecol. 2015

Equipe despreparada

Centralisation of services for gynaecological cancer

Dr. Marcelo Simonsen
GINECOLOGIA LAPAROSCÓPICA
ONCOLOGIA GINECOLÓGICA

Analysis 1.1. Comparison 1 Institutions with gynaecologic oncologists on site (specialised centres) vs. community or general hospital, Outcome 1 Ovarian cancer: survival.

Review: Centralisation of services for gynaecological cancer

Comparison: 1 Institutions with gynaecologic oncologists on site (specialised centres) vs. community or general hospital

Outcome: 1 Ovarian cancer: survival

Study or subgroup	Specialised centre N	General hospital N	log [Hazard Ratio] (SE)	Hazard Ratio IV,Random,95% CI	Weight	Hazard Ratio IV,Random,95% CI
1 Overall survival						
Elit 2002	1281	1732	-0.099 (0.086)		31.7 %	0.91 [0.77, 1.07]
Stockton 2000	475	514	-0.114 (0.074)		42.8 %	0.89 [0.77, 1.03]
Subtotal (95% CI)	**1756**	**2246**			**74.5 %**	**0.90 [0.80, 1.00]**
Heterogeneity: $Tau^2 = 0.0$; $Chi^2 = 0.02$, df = 1 (P = 0.89); $I^2 = 0.0\%$						
Test for overall effect: Z = 1.92 (P = 0.055)						
2 Disease-specific survival						
Vernooij 2008	1557	3482	-0.106 (0.096)		25.5 %	0.90 [0.75, 1.09]
Subtotal (95% CI)	**1557**	**3482**			**25.5 %**	**0.90 [0.75, 1.09]**
Heterogeneity: not applicable						
Test for overall effect: Z = 1.10 (P = 0.27)						
Total (95% CI)	**3313**	**5728**			**100.0 %**	**0.90 [0.82, 0.99]**
Heterogeneity: $Tau^2 = 0.0$; $Chi^2 = 0.02$, df = 2 (P = 0.99); $I^2 = 0.0\%$						
Test for overall effect: Z = 2.21 (P = 0.027)						
Test for subgroup differences: $Chi^2 = 0.00$, df = 1 (P = 0.99), $I^2 = 0.0\%$						

Woo et al 2012

The Relevance of Gynecologic Oncologists to Provide High-Quality of Care to Women with Gynecological Cancer

Dr. Marcelo Simonsen
GINECOLOGIA LAPAROSCÓPICA
ONCOLOGIA GINECOLÓGICA

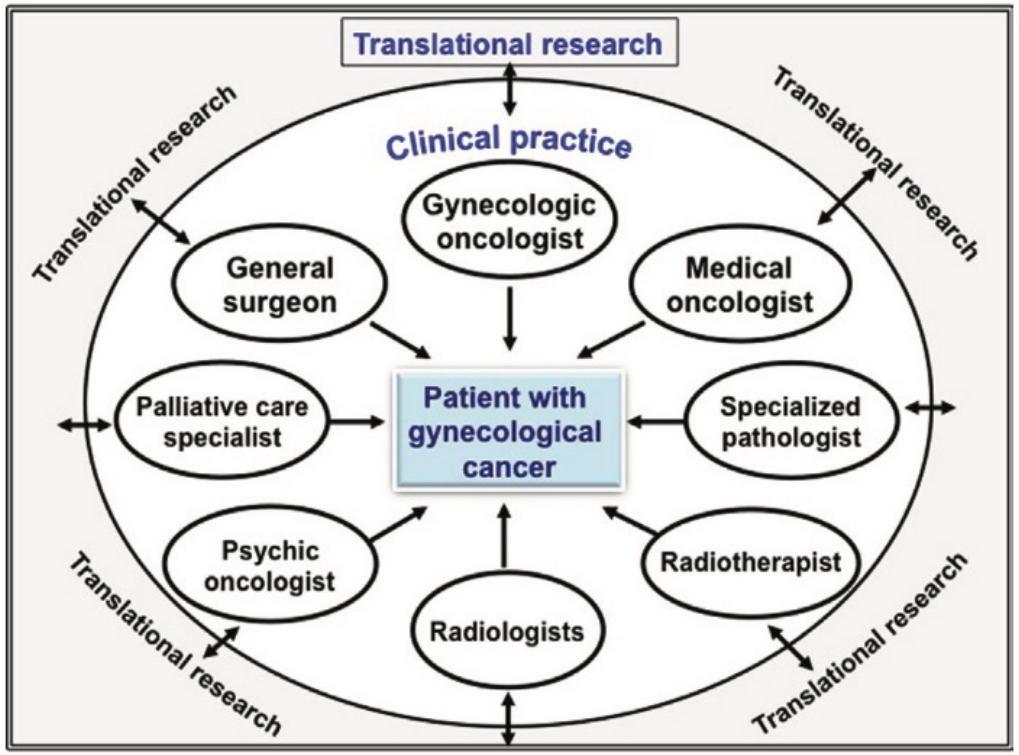

FIGURE 1 | Multidisciplinary team to treat women with gynecological cancer.

Minig et al; frontiers in oncology 2016

Paciente despreparada

Dr. Marcelo Simonsen
GINECOLOGIA LAPAROSCÓPICA
ONCOLOGIA GINECOLÓGICA

- Maioria das pacientes não sabe da similaridade clínica de miomas e sarcomas

- Em caso de sarcoma:
- Ciente da possibilidade do impacto prognóstico do morcelamento?
- Ciente da possibilidade de reabordagem?
- Possibilidade de adjuvância?

Aspectos clínicos

Dr. Marcelo Simonsen
GINECOLOGIA LAPAROSCÓPICA
ONCOLOGIA GINECOLÓGICA

- 25% assintomáticas
- 50% sangramento irregular
- Tamanho variável do útero
- 55 anos
- Tendência a estádio inicial
- Sobrevida 5 anos: 77% achado inadvertido vs 46% presumido

(mas 97% com achado inadvertido E inicial!)

Cheng et al. BMC Women's Health (2022) 22:495

Critérios clínicos isolados para presunção...

Dr. Marcelo Simonsen
GINECOLOGIA LAPAROSCÓPICA
ONCOLOGIA GINECOLÓGICA

TABLE 2. Univariate Analysis of Clinical Parameters for the Uterine Sarcoma and Atypical Leiomyoma Groups

	Uterine Sarcoma ($n = 60$)	Atypical Leiomyoma ($n = 88$)	P
Age (y), range	46 ± 12, 20–76	42 ± 9, 21–77	.019
BMI (kg/m^2)	20.93 ± 3.84	22.71 ± 2.89	.961
Childbearing history			
Nulliparity	7	15	.366
Abortion	45	74	.171
Clinical manifestation			
Abnormal vaginal bleeding	23	4	**<.001**
Menstrual changes*	19	22	.374
Abdominal pain	9	11	.662
Pelvic mass	5	9	.699
Urinary symptoms	2	3	1.000
Physical examinations	2	39	<.001
CA125 ↑ (>35 U/mL)†	14	14	.128
LDH ↑ (>245 U/L)‡	8	4	.020
Serum albumin ↓ (<40 g/L)§	30	31	.064
FIGO stage			
Stage I	54	–	–
Stage II	6	–	–

Bi et al Academic Radiology, 2018

Soluções

Dr. Marcelo Simonsen
GINECOLOGIA LAPAROSCÓPICA
ONCOLOGIA GINECOLÓGICA

- Tentar presumir malignidade
- Não assumir casos em que a equipe não esteja preparada
- Compartilhar sempre a possibilidade de malignidade
- Minimizar impacto negativo do morcelamento

Tentar presumir antes da cirurgia

- Aspectos radiológicos
- Todas as pacientes com miomas sintomáticos deveriam realizar RNM

Napoli et al – Obstet and Gynecol cases 2018

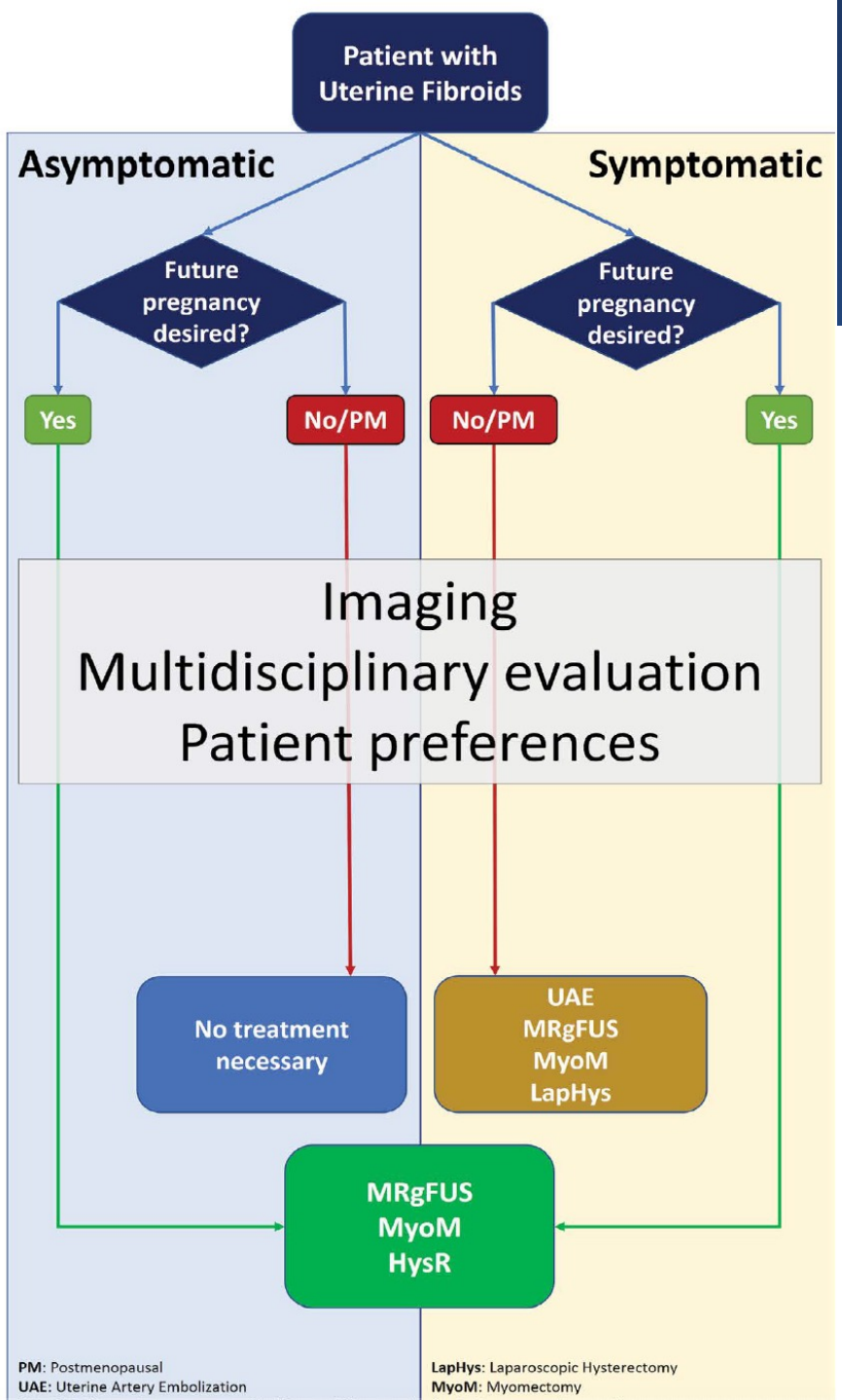

Aspecto da imagem RNM

Dr. Marcelo Simonsen
GINECOLOGIA LAPAROSCÓPICA
ONCOLOGIA GINECOLÓGICA

Table 1. MRI features of leiomyomas and subtypes versus leiomyosarcomas

	Ordinary LM	Degenerated LM	Highly cellular LM	LMS
Border	Well defined; can show a low T2 pseudocapsule (peri-tumoral edema due to venous/lymphatic compression)			Irregular, nodular or lobulated
Enhancement	Variable, generally homogeneous	Heterogeneous with non-enhancing areas (hyaline degeneration, cystic components, red degeneration)	Avid, generally homogeneous	Early, heterogeneous, with central poor enhancement (necrotic areas)
High T1WI SI (hemorrhage)	Absent (low T1WI SI)	Present in red degeneration (infarction-type necrosis)	Absent (low T1WI SI)	Present (areas of high T1WI SI)
T2WI SI	Low T2WI SI	High in myxoid/cystic degeneration and oedematous areas	Intermediate-to-high T2WI SI	Intermediate-to-high areas mixed with "T2 dark" areas
Endometrial interface	Can appear displaced or compressed, but preserved; no endometrial thickening			Disrupted, thickened endometrium
Restricted Diffusion	Absent	Present in red degeneration (hemorrhage can restrict diffusion)	Present (high cellularity)	Present (high cellularity of the solid component)
ADC values ± SD (10–3mm2/s)	0.88 ± 0.27 to 1.40 ± 0.31	1.17 ± 0.17 to 1.7 ± 0.11	1.13 ± 0.18 to 1.43 ± 0.58	0.79 ± 0.21 (SD) to 1.17 ± 0.1

Coeficiente de difusão aparente

Bura et al Br J Radiol 2021

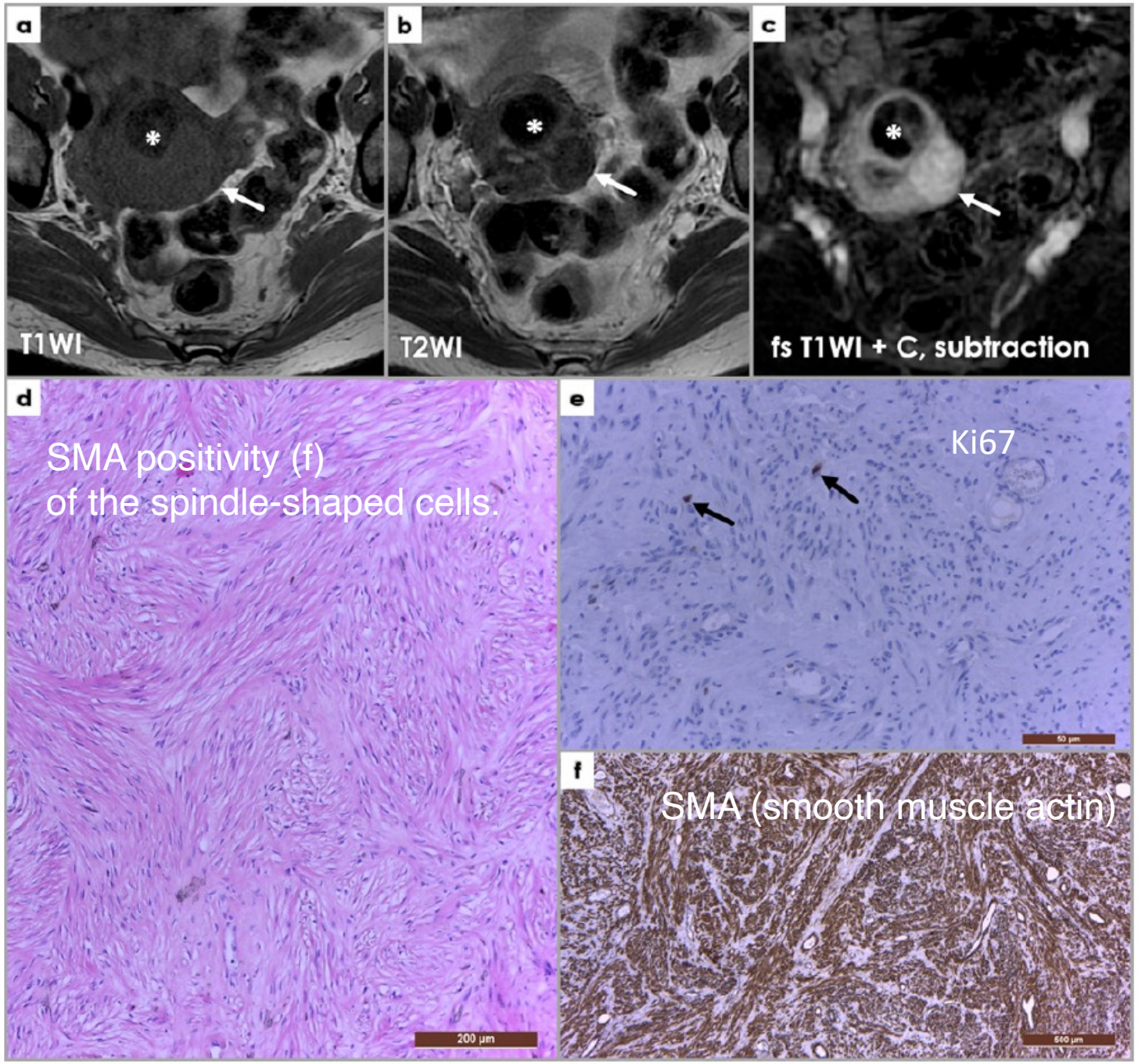

Mioma com degeneração
Hialina e mioma convencional

Bura et al Br J Radiol 2021

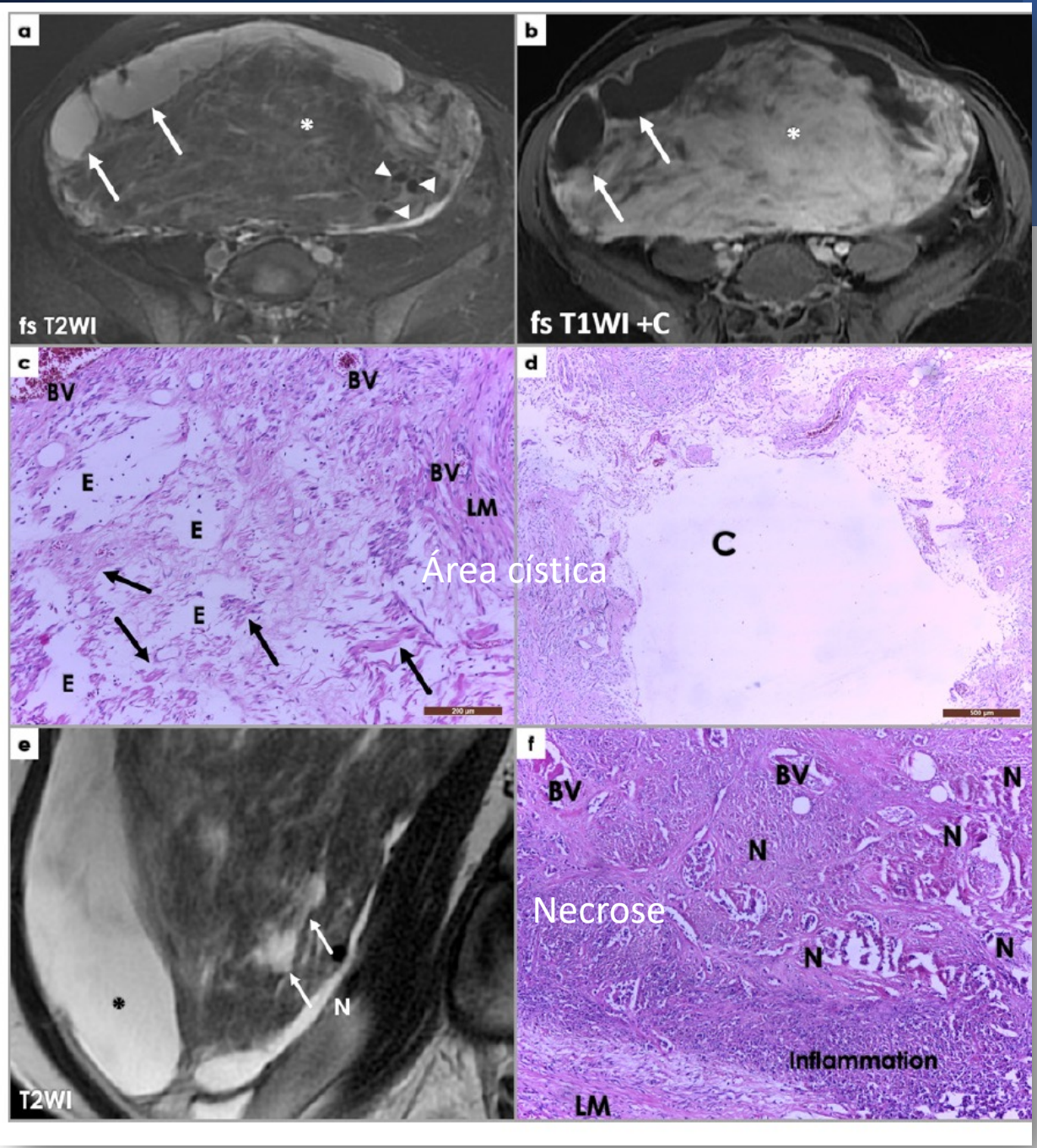

mioma com
degeneração cística
e necrose

Bura et al Br J Radiol 2021

Degeneração mixóide envolvendo mioma cístico

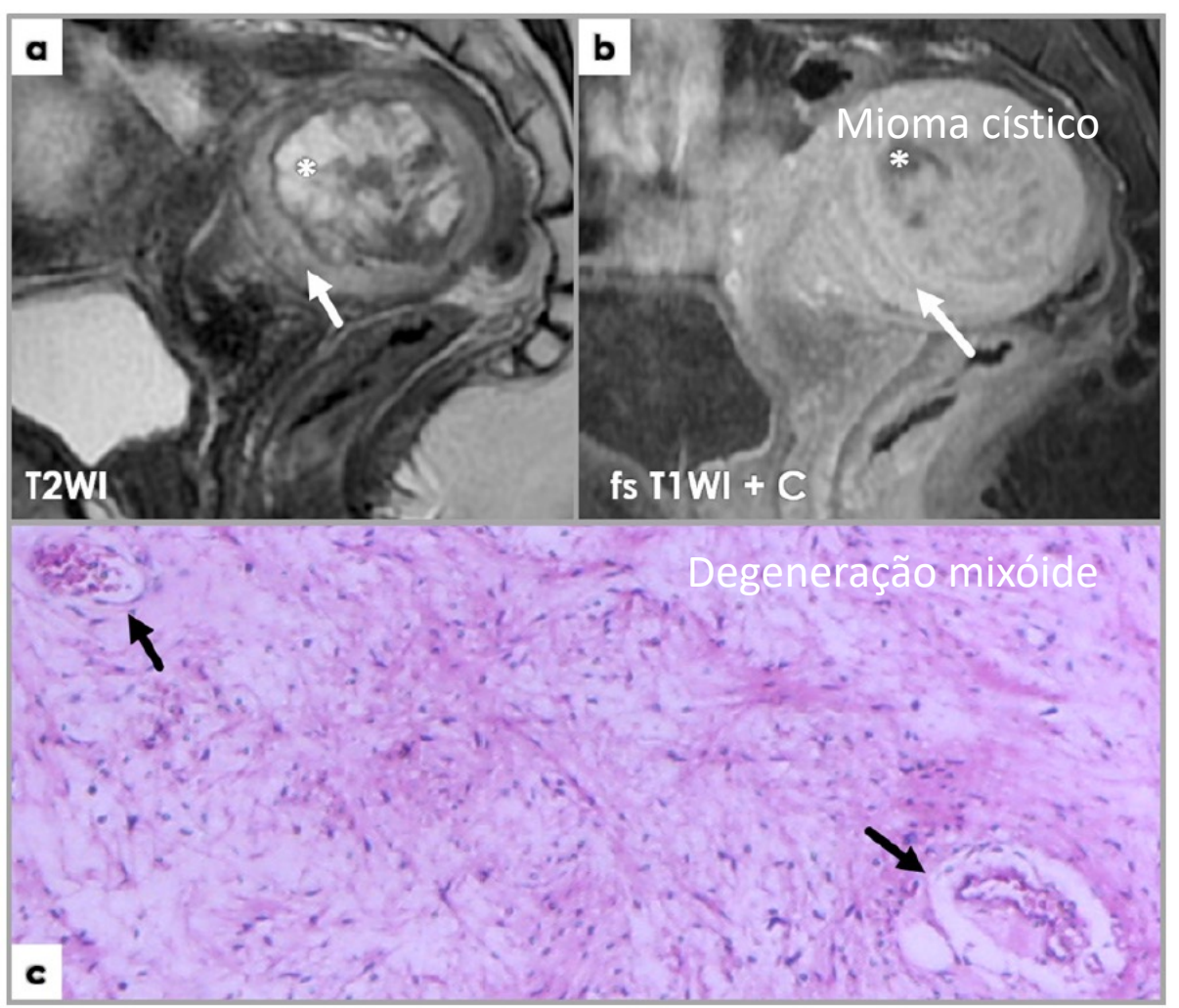

Bura et al Br J Radiol 2021

Suspeito - Leiomiossarcoma

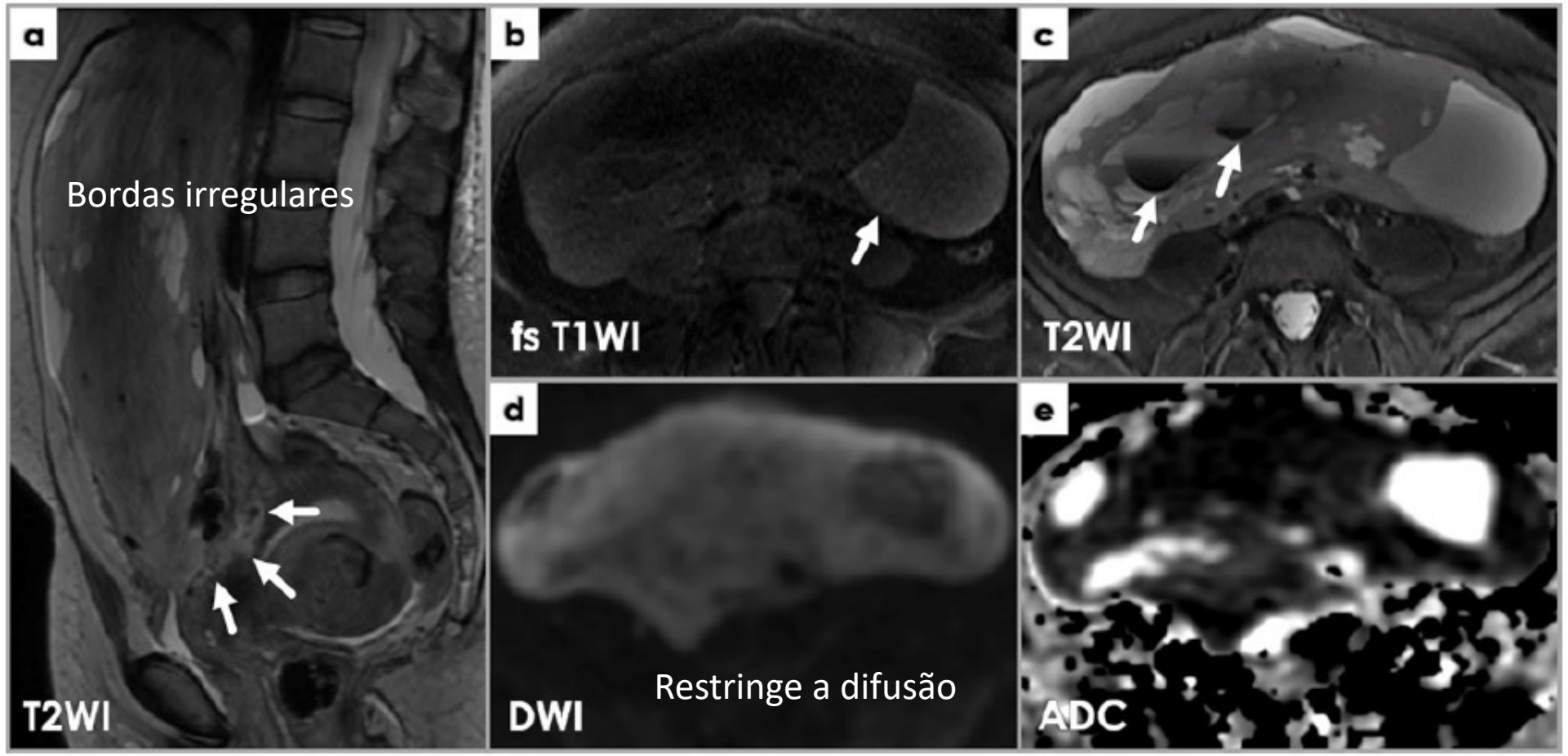

Bura et al Br J Radiol 2021

Carcinossarcoma

Dr. Marcelo Simonsen
GINECOLOGIA LAPAROSCÓPICA
ONCOLOGIA GINECOLÓGICA

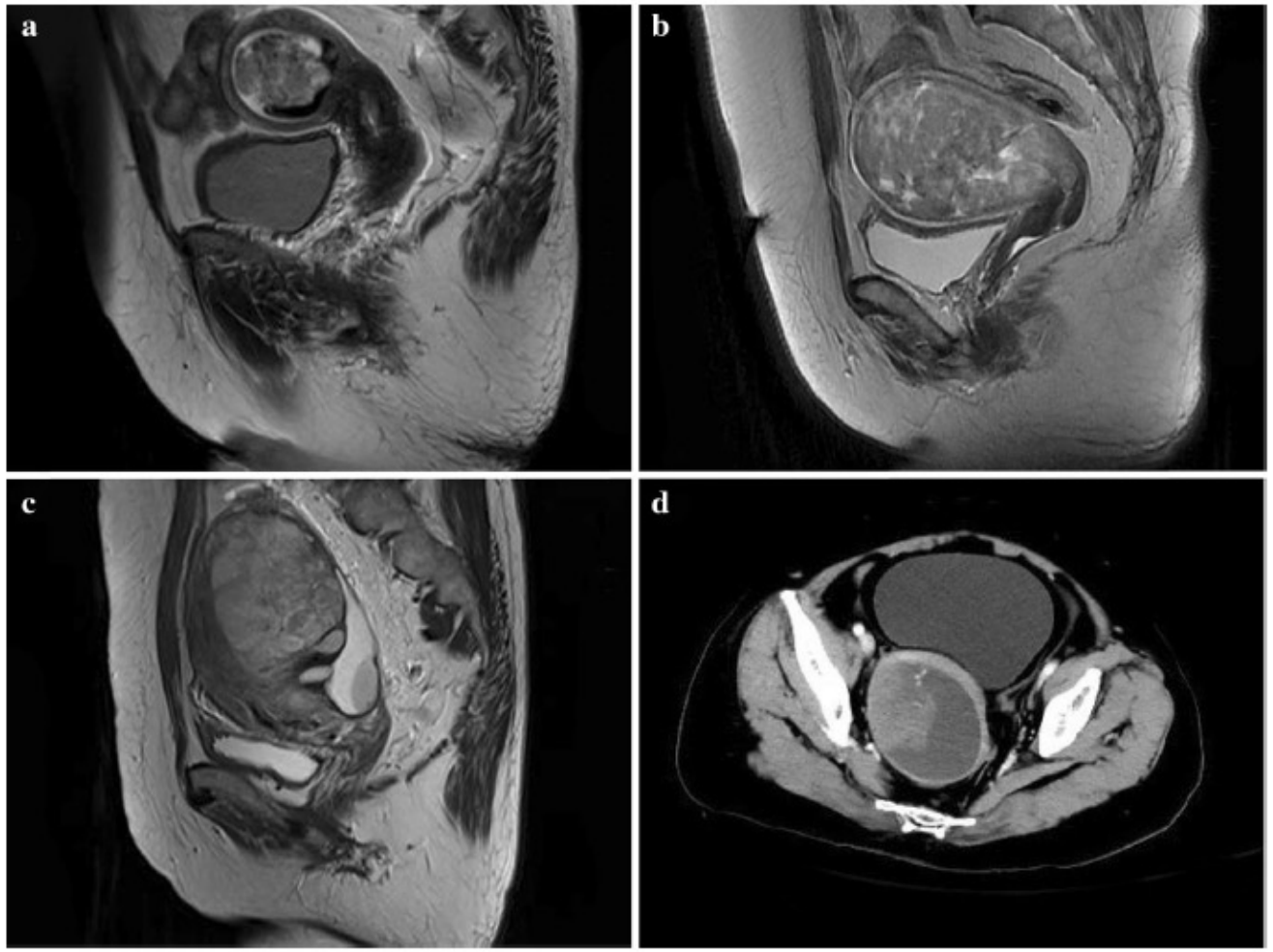

Fig. 4 Images of uterine carcinosarcoma (UCS). Sagittal T2WI magnetic resonance imaging (MRI) of a 64-year-old woman (**a**) showed a mixed signal tumor in the cavity with multiple small round or irregular cystic areas in the internal tumor. Sagittal T2WI MRI of a 66-year-old woman (**b**) showed a mixed signal tumor in the cavity with many gap-like cystic areas. Sagittal T2WI MRI of a 49-year-old woman (**c**) showed a high signal tumor in the cavity with many oval cystic areas. Axial computed tomography (CT) images in the venous phase (**d**) of a 66-year-old woman showed a tumor mainly composed of cystic components. The tissue components showed nipple-like enhancement with a marginal cystic component

Li et al Insights into Imaging 2021

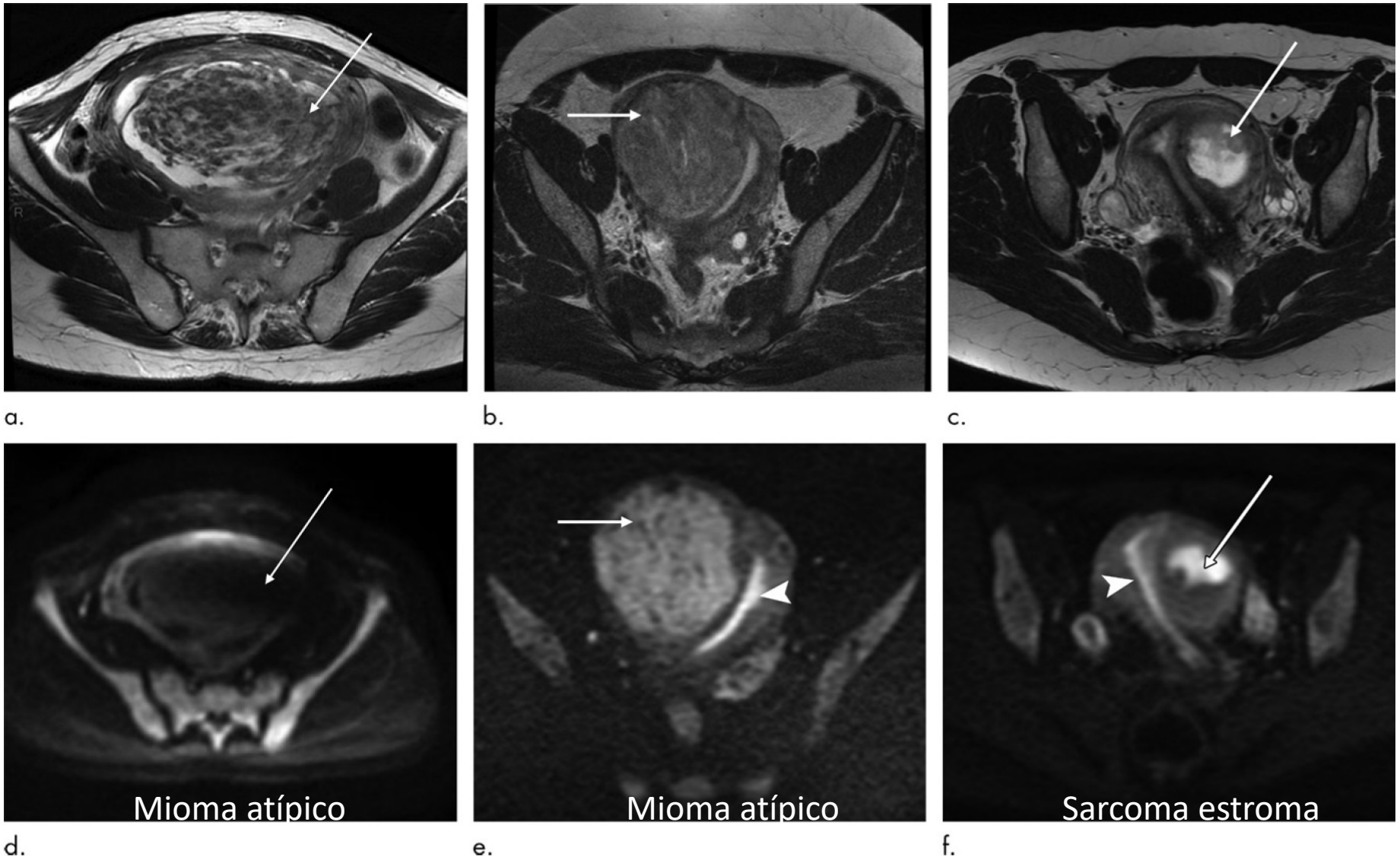

Figure 2: Examples of visual categories of diffusion-weighted imaging signal intensity (b = 1000 sec/mm^2) in three masses with corresponding T2 sequences. **(a, d)** Images depict atypical leiomyoma (arrow) with, respectively, heterogeneous signal intensity on T2-weighted images and low signal intensity on diffusion-weighted images. **(b, e)** Images represent atypical leiomyoma (arrow) with, respectively, intermediate signal intensity on T2-weighted images and intermediate diffusion-weighted imaging signal intensity higher than that in myometrium but lower than in endometrium (arrowhead). **(c, f)** Images show endometrial stromal sarcoma (arrow) with, respectively, intermediate signal intensity on T2-weighted images and high diffusion-weighted imaging signal intensity higher than that in endometrium (arrowhead).

Wahab et al; Radiology 2020

Benigno vs maligno

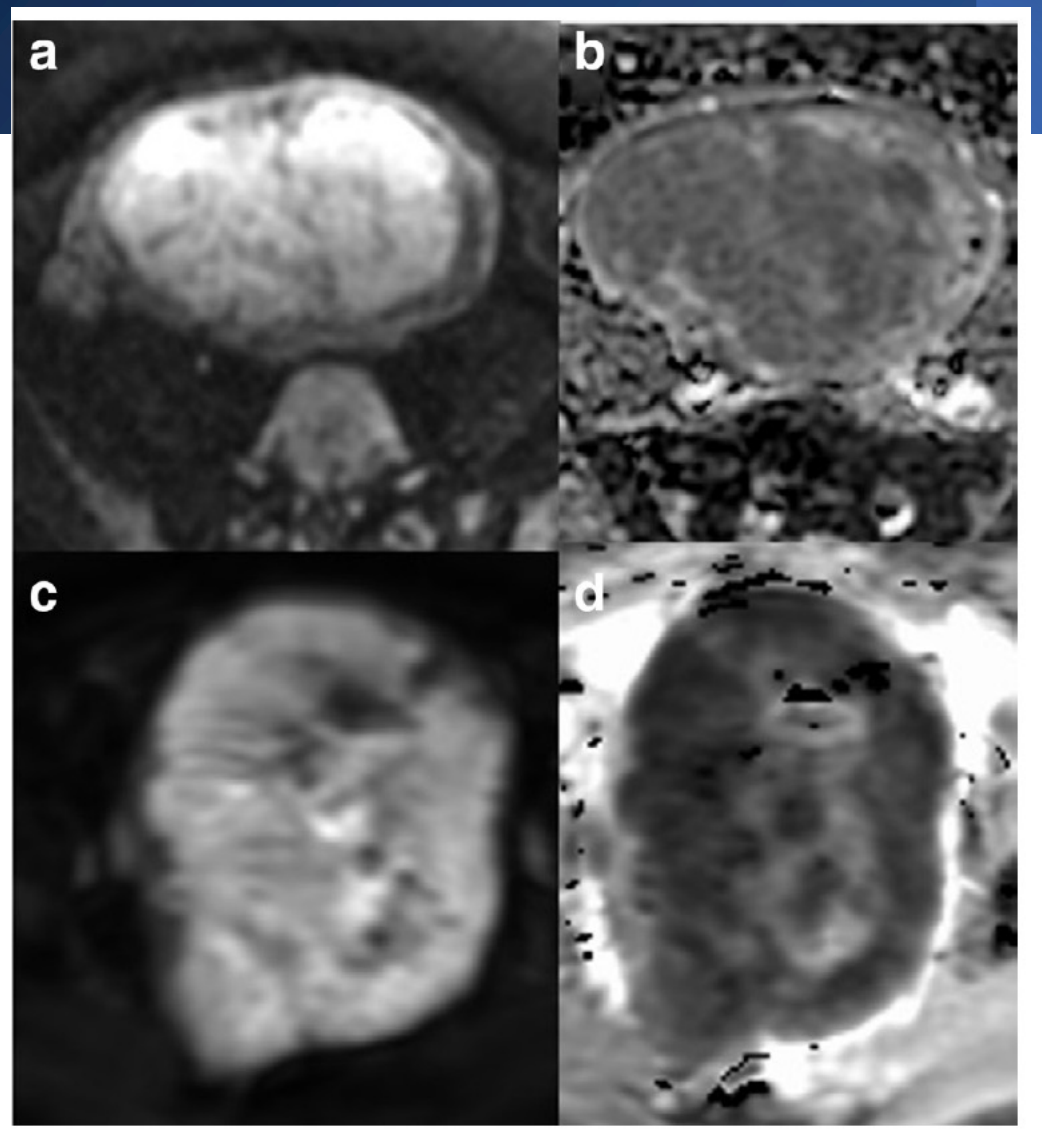

Benigno

Maligno

Bura et al Br J Radiol 2021

Algoritmo

Sensibilidade 98% e especificidade 96%
Treinamento:
Sensibilidade 88% e especificidade 83%

Wahab et al; Radiology 2020

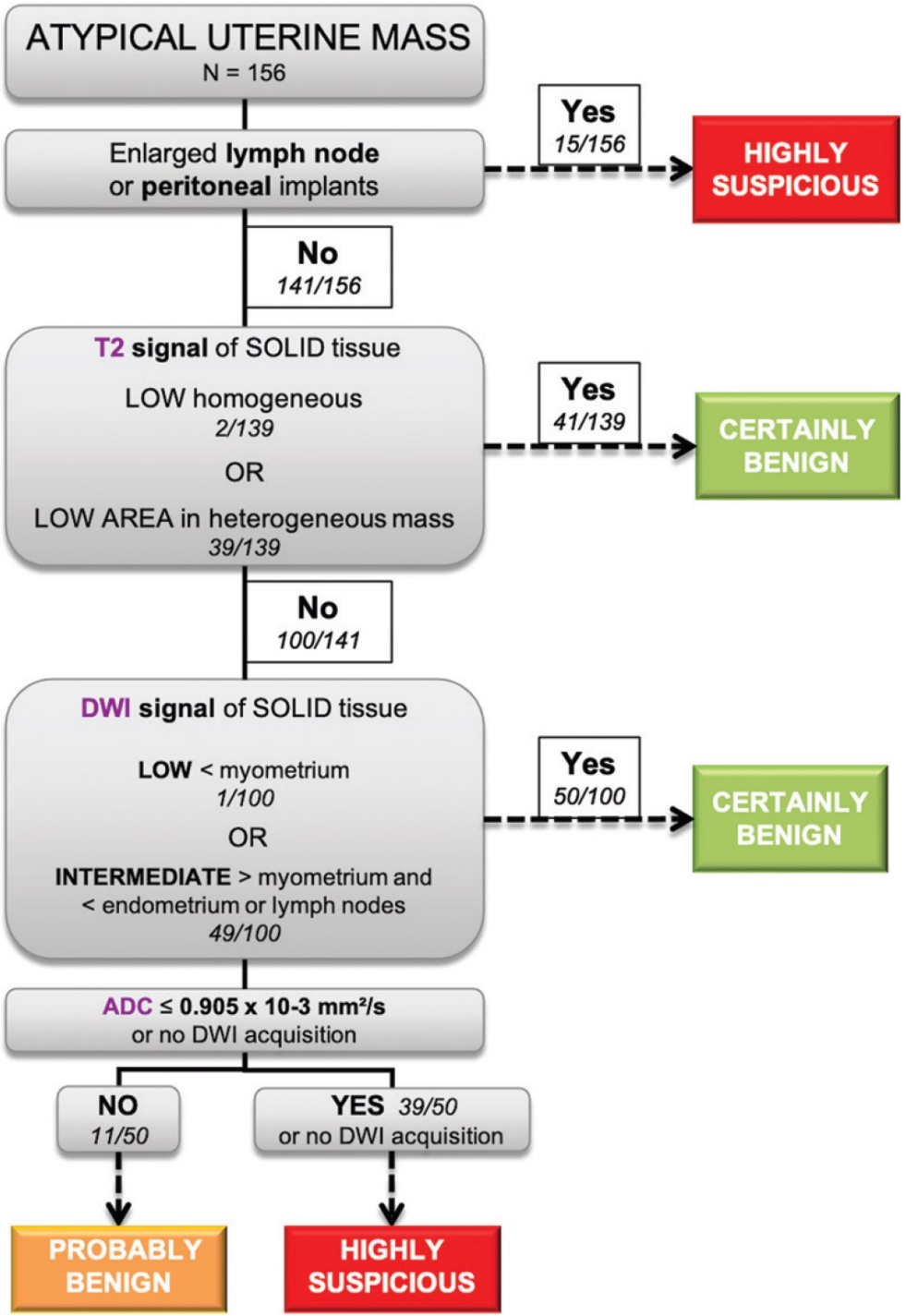

Critérios clínico-radiológicos!

Dr. Marcelo Simonsen
GINECOLOGIA LAPAROSCÓPICA
ONCOLOGIA GINECOLÓGICA

TABLE 4. Predictive Values of Each Predictive Factor

	Odds Ratio	*P*	Parameter Estimates	Predictive Values (Points)
Abnormal vaginal bleeding	13.054	.000	2.569	3
Located in the uterine cavity	26.159	.040	3.264	3
Ill-defined margin on T2WI	81.206	.000	4.397	4
Mean ADC $< 1.272 \times 10^{-3}$ mm^2/s	99.371	.001	4.599	5
Type III of the TICs of the lesions	1.149	.888	0.139	—

ADC, apparent diffusion coefficient; T2WI, T2-weighted imaging; TIC, time signal-intensity curves.
P, obtaining predictive factors by multivariable logistic regression analysis with a value of $P < .05$.

Sensibilidade 88% e especificidade 99%

Bi et al Academic Radiology, 2018

Conclusões

Dr. Marcelo Simonsen
GINECOLOGIA LAPAROSCÓPICA
ONCOLOGIA GINECOLÓGICA

- Morcelar sarcomas compromete prognóstico
- Usar critérios clínicos/ radiológicos pré operatórios para presunção
- Se risco elevado cirurgia aberta
- Se risco baixo realizar morcelamento protegido

Dr. Marcelo Simonsen
GINECOLOGIA LAPAROSCÓPICA
ONCOLOGIA GINECOLÓGICA

Obrigado!

drmarcelosimonsen@gmail.com